

650 Riverbend Drive, Suite C  
Kitchener, Ontario, Canada N2K 3S2  
Phone +1-519-578-2740  
Fax +1-519-578-1870  
www.hybridturkeys.com

## Cellulitis in Turkeys

Cellulitis is a general term which encompasses a variety of defects or lesions involving inflammation of the skin. In turkeys, these lesions primarily involve the breast area. Specific terms used to describe the range of lesions present include: focal ulcerative dermatitis, breast button, breast blister, folliculitis and contact dermatitis. All of these lesions occur on the central unfeathered areas of the breast, with breast buttons and blisters being the most significant economically. Breast lesions can range from areas containing blood tinged, often jelly-like material to thick white purulent abscesses. In general, these lesions do not affect the turkey but they are an expensive problem for the grower and processing plant. The USDA New Turkey Inspection System (NTIS) states that breast blisters with inflammatory tissue, fluid or pus, between the skin and keel, must be trimmed if membrane “slips” are felt, or if a firm nodule is greater than ½ inch (1.3 cm)<sup>1</sup>. Wing abscesses may also be included in the cellulitis category. The decision to trim or condemn depends on the size of the lesion, the line speed and company specifications.

### Brief Description of Terms

**Breast Buttons** usually occur on the unfeathered area of the breast skin or near the upper part of the keel bone. They have a raised ring with a central granulomatous core. They are rarely seen prior to 10 weeks of age, with peaks between 16 to 18 weeks of age, especially in toms. It is interesting to note that there are no reports in the literature on this condition prior to 1980.

**Breast Blisters** are an enlargement or thickening of the normal bursal sac present along the keel bone. For this reason, breast blisters may be referred to as

Enlarged Sternal Bursa (ESB). They are often present beneath breast buttons. They can arise from a breast button that perforates into the sternal bursa and causes a bursitis. The initial change occurs between the layers of the skin with swelling and accumulation of fluid.

**Contact Dermatitis** refers to the flat, scab-like lesions associated with wet litter and poor environment. Affected birds have a high incidence of burns on their hocks and footpads. It is superficial and can be peeled off.

**Folliculitis** is an inflammation of the feather follicles lateral to the sternal bursa.

**Focal Ulcerative Dermatitis (FUD)** are circumscribed areas where the skin is broken and infected. Breast buttons and contact dermatitis have been termed primary and secondary FUD, respectively. Breast blisters and folliculitis should be considered distinct from FUD.

**Sternal Bursa** is a small sac present on the ventral aspect of the keel. The lining is composed of a typical synovial membrane similar to the hock joint, which produces a small amount of fluid. An enlarged sternal bursa occurs primarily from continual irritation due to pressure or friction on the anterior keel.<sup>6</sup> Irritation causes the bursa to enlarge by stimulating the lining to produce more fluid and causing chronic inflammation in surrounding tissues.<sup>8</sup>

### What Causes Cellulitis?

Cellulitis occurs in turkeys throughout North America with the incidence being higher in toms

than broilers or hens (21% versus 2%)<sup>5</sup>. However, over the past five years as weights of heavy hens have increased, so has the incidence of cellulitis.

The following factors have been shown to contribute to breast buttons and blisters:

- litter quality
- feather covering over the keel
- high average daily gains
- body weight
- photoperiod
- infectious agents
- breed/strain of turkey

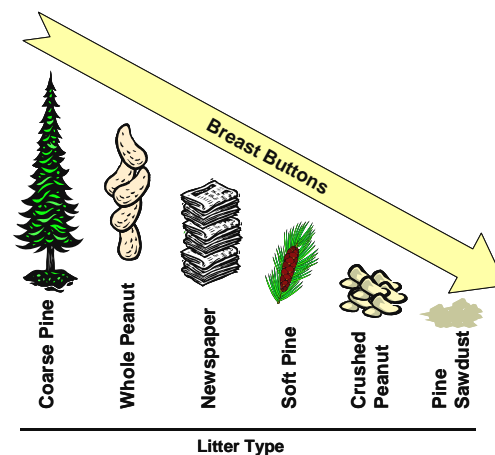
Two factors not associated with cellulitis are angular leg deformities<sup>7</sup> and toe trimming<sup>5,7</sup>. Although toms with twisted legs spend more time lying down, their weights are generally lighter which appears to be a more significant factor<sup>2</sup>. This however is not to say that turkeys with other types of leg problems (such as tibial bowing due to heavy weight) would not have a higher incidence. In one trial, turkeys with intact toes were shown to be almost one pound (0.44kg) heavier at 17 weeks than those with clipped toes<sup>7</sup>.

### Litter Quality

Litter which has gotten wet then dried into large chunks has also been shown to be irritating to the breast area<sup>2</sup>. Litter containing a high level of ammonia is thought to be one of the primary factors contributing to or initiating the development of breast blisters. It is theorized that volatile ammonia (that not trapped in the litter but released), when in contact with the thin skinned, unfeathered areas of the breast, causes irritation of the epidermis and constriction of the blood vessels supplying the area. This leads to fluid accumulation between the epidermis and the dermis. The role of litter moisture is difficult to determine. Wetting of the litter to 60-70% moisture increased the

incidence of breast blisters. Wetting turkey ranges every third day decreased the incidence.

The highest to lowest incidence of breast buttons occur with the following litter types:<sup>10</sup>



### Feather Covering

There is a definite association between breast lesions and the width of the unfeathered skin over the keel. Experimentally, turkeys with coverings placed over the breast area resulted in zero breast defects<sup>2</sup>. Selection for increased breast muscle may result in poor feather cover as the skin is stretched to cover a larger area without an increase in the number of feather tracts. The growth of breast feathers in the cranial region of the breast appears to be impaired in the modern turkey as compared to the wild turkey<sup>11</sup>. Experimental work has shown that lowering the dietary protein concentration of feed increased the length of the cranial breast feathers by 78%, which would be an advantage to preventing breast lesions<sup>11</sup>. However it also reduced the body weight by 44% which is not economically acceptable. Further work also showed that supplementing a basal diet of 180g CP/kg with amino acids such as tyrosine, arginine, methionine or valine increased body weight but decreased the length of cranial breast feathers<sup>11</sup>.

## High Average Daily Gains and Body Weight

There is a seasonal trend in incidence of breast blisters with lower levels reported early in the year, increasing in April and May, peaking in June or July and then gradually decreasing. Historically the incidence of breast blisters in heavy toms, in the USA, during the summer months has increased annually from 4% in 1984 to 15% in 1990 to a high of 25% in 1997<sup>3</sup>. Since that time slight improvement has been seen.

Flocks with the fastest growth rates also have the highest incidence of breast buttons. In two trials, 12-week-old toms with buttons weighed an average of 0.4 - 0.55 lbs (0.19 - 0.25 kg) heavier than toms without breast buttons<sup>7</sup>. In a University of Minnesota trial, toms raised on slotted flooring weighed approximately 3 to 4 lbs (1.4 - 1.8 kg) heavier than toms raised on litter but had a greater incidence of breast buttons and blisters<sup>4</sup>.

## Photoperiod

Trials using increasing daylength (8 to 23 hours) from 4 to 16 weeks showed a significant decrease in breast buttons as compared to a constant (23L:1D) photoperiod. Toms grown on increasing day length were more active and spent less time lying down with their breast in contact with the litter. Their feathering and skin were visually cleaner<sup>7</sup>. Research is lacking on the effect of photoperiod on the incidence of other types of breast lesions.

## Infectious Agents

*Mycoplasma synoviae* will infect the sternal bursa causing inflammation and enlargement. The blisters produced tend to be large and baggy with lots of fluid in them<sup>2</sup>. No perforating ulcers are present. It has been shown that when turkeys are stressed the level of bacteria present in their bloodstream increases rapidly and dramatically. These bacteria can localize in the sternal bursae or in a pre-existing blister causing inflammation and

infection. Experimentally, this has been reproduced by withdrawing feed for 24 hours<sup>4</sup>. This stress resulted in the colony forming units of *Staphylococcus aureus*, increasing by 106% in the bloodstream and over 300% in the sternal bursa itself, resulting in a higher incidence of breast blisters.

## Breed or Strain of Turkey

There are breed differences in large white turkeys in the amount of unfeathered skin (distance between the feather tracts) over the keel. Breast conformation is also significant. If the keel bone is prominent the incidence of blisters increases. A 1996 report from North Carolina reported that Hybrid toms had a lower incidence of breast buttons than Nicholas or BUTA raised under the same environmental conditions<sup>10</sup>.

## Prevention of Cellulitis

### Litter Management

It appears that the physical characteristics of the litter are more significant than chemical treatment. However, reducing the ammonia and increasing the acidity of the litter should help control the incidence and severity of breast buttons and blisters. Maintaining litter pH as low as 7.0 reduces the release of ammonia from the litter into the air since more ammonia will be in the ionized form ( $\text{NH}_4^+$ ) at this pH<sup>9</sup>. Poultry Litter Treatment (PLT) has been reported to decrease the incidence from 34.8% to 26%.

Much to the dismay and surprise of growers who have placed grow-out flocks on new litter in an attempt to reduce the level of breast lesions, the incidence did not decrease but instead increased. This may be because the flocks were not slowed down by bacterial and viral challenges which resulted in better weights and higher average daily gains. It may also relate to the poorer ammonia-holding ability of new litter versus old.

## Growth Management

Presently we do not know where the breaking point is between the gains made through high average daily gains and superior feed conversion and the losses from downgrades and condemnations due to breast buttons and blisters. In addition, we do not know how to manage the growth rate sufficiently to still end up at the same market weights. For production of whole body birds, using a different strain such as a medium or heavy medium versus a large white has proven beneficial.

Gentle handling during loadout is important in a flock with a high incidence of breast blisters. If a blister is bumped during loadout, there may be bleeding into it, which will draw more attention at the processing plant and may lead to excessive trimming<sup>2</sup>.

## Conclusion

Cellulitis is very likely a multifactorial condition with the three main variables being: breed or strain of turkey, high average daily gains and litter quality. The amount of research done on breast buttons and blisters is minimal compared to the lost revenue to the industry.

## References

1. Clark, S. and Hansen, G. Breast Blisters in Turkeys. Alpha Technical Information Sheet.
2. Elanco Turkey Technical Symposium. Open Forum Panel. Dr. J. Barnes, Dr. T. Brown, Dr. K. Klasing, Dr. M. Novilla and Dr. Larry Pendelton. Pgs. 42 - 46
3. Hansen, G. 1999. Major Factors Affecting Turkey Carcass Downgrading in the Plant. Proceedings of the North Carolina Turkey Days Conference. Pgs. 35 - 40.
4. Kamyah, A., Noll, S., Halvorsen, D., Nagaraja, K.V., Sivanandan, V., Shaw, D., Janni, K., And Trites, J. 1997. Breast Blister Formation in Market Tom Turkeys – Does Stress Play a Role? *Gobbles*. Oct. Pgs 14 - 17.
5. McEwen, S.A. and Barbut, S. 1992. Survey of turkey downgrading at slaughter: carcass defects and associations with transport, toenail trimming and type of bird. *Poultry Science* 71: 1107 - 1115.
6. Miner, M.L. and Smart, R.A. 1975. Causes of enlarged sternal bursas (breast blisters). *Avian Diseases*, 19: 246 - 25.
7. Newberry, R, C. 1992. Influence of Increasing Photoperiod and Toe Clipping on Breast Buttons of Turkeys. *Poultry Science*. 71 : 1471 - 1479.
8. Pass, D.A. 1989. The Pathology of the Avian Integument : A Review. *Avian Pathology*. 18 : 1 - 72.
9. Rehberger, T. 2002. The Importance of litter Management in Controlling Microbiological Challenges in Turkey and Broiler Production Systems. *Proceedings of the Midwest Poultry Federation* . pgs. 130 - 144.
10. Tilley, B., Barnes, H.J., Scott, R., Rives, D.V., Brewer, C.E. Gerig, T., Jennings, R.S., Coleman, J., and Schmidt, G.. 1996. Litter and Commercial Turkey Stain on Focal Ulcerative Dermatitis ("Breast Buttons"). *Applied Poultry Science*. 5: 39 - 50.
11. Wylie, L. M. and Hocking, P.M. 2000. Investigating feather growth as a means of preventing breast lesions in turkeys. *Turkeys Technical Conference*.

© Hybrid Turkeys

Unless otherwise specified, the information provided here is the property of Hybrid Turkeys. Before reproducing or publishing this material in any manner, please obtain approval by calling Hybrid Turkeys' head office in Kitchener, Ontario, Canada at +1-519-578-2740.